University of Pittsburgh

Interventional Pulmonology: Minimally Invasive Procedures for the Diagnosis and Management of Pulmonary Disease

Roy W. Semaan, M.D.
Director, Interventional Pulmonology
Assistant Professor of Medicine
Division of Pulmonary Allergy & Critical Care Medicine
University of Pittsburgh Medical Center

Disclosures

- None

Objectives

- The Current Clinical Scope of Interventional Pulmonology
  - Lung cancer screening
  - Advanced Diagnostic Bronchoscopy
  - Therapeutic Bronchoscopy
  - Minimally Invasive Pleural Procedures

- Central Airway Obstruction
  - Basics
  - Causes and
  - Current and Future Research

The Current Clinical Scope of IP

Lung Cancer Screening: NLST



The NEW ENGLAND JOURNAL of MEDICINE

ESTABLISHED IN 1812 AUGUST 4, 2011 VOL. 365 NO. 5

Reduced Lung-Cancer Mortality with Low-Dose Computed Tomographic Screening

The National Lung Screening Trial Research Team*

20% relative reduction in mortality with routine low dose CT scans vs. routine radiography

Early screening infrastructure now in place

The NEW ENGLAND JOURNAL of MEDICINE

National Lung Screening trial results published In NEJM. Low dose CT scanning reduces mortality by 20%

U.S. Preventive Services TASK FORCE

The United States Preventative Services Task Force Guidelines recommend mandatory screening/payment

CMS

The Center for Medicare and Medicaid Services (CMS) approved NLST Lung Cancer Screening. Covered 1X per year

CHEST AMERICAN COLLEGE of CHEST PHYSICIANS

The American College of Chest Physicians (ACCP) Guidelines: Electromagnetic Navigated Bronchoscopy is one of the recommended procedures for the diagnosis of peripheral lung nodules

CMS

Who Qualifies for Low Dose CT Screening?

- Adults age 55-80
- 30 pack-year smoking history
- Currently smoke or quit within 15 years
- Willingness to undergo further diagnostic procedures
- No other health problem that substantially limits life expectancy.

Ways to Biopsy Lung Nodules

- CT Guided TTNA
  - Higher diagnostic yield
  - Higher rate of pneumothorax ~15-20%
  - Inability to stage the mediastinum

- Bronchoscopy
  - Lower diagnostic yield
  - Lower rate of pneumothorax ~5%
  - Can simultaneously pathologically stage the mediastinum with EBUS

- VATS/Thoracotomy Wedge Biopsy
  - Highest yield
  - Surgical procedure with morbidity
  - All patients require post operative chest drain and admission

Advanced Diagnostic Bronchoscopy

- Endobronchial ultrasound (EBUS):
- Electromagnetic navigational bronchoscopy
- Electromagnetic virtual CT TTNA

Endobronchial Ultrasound

- The use of ultrasound to visualize mediastinal/hilar lymph nodes and parenchymal lung lesions for biopsy

- Two general types:
  - Radial Probe EBUS
  - Linear/Convex Probe EBUS

Linear/Convex Probe EBUS

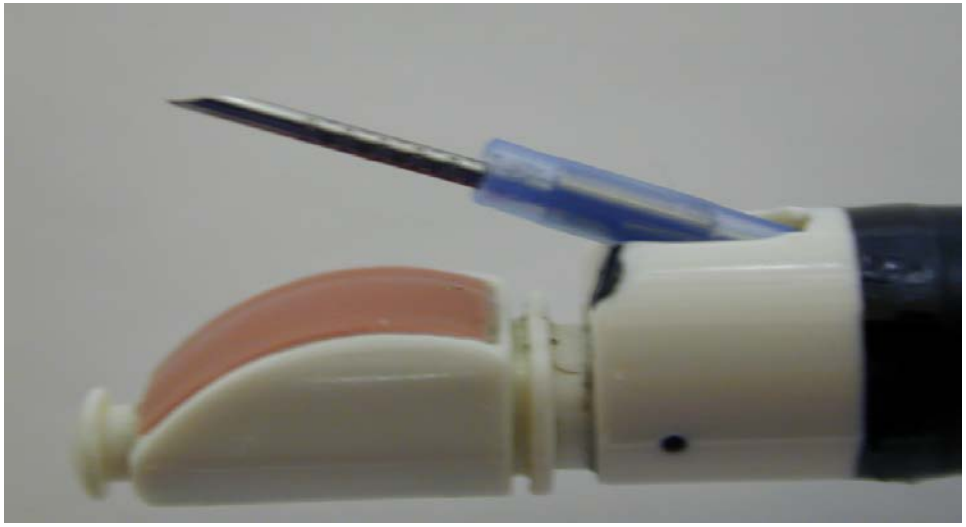

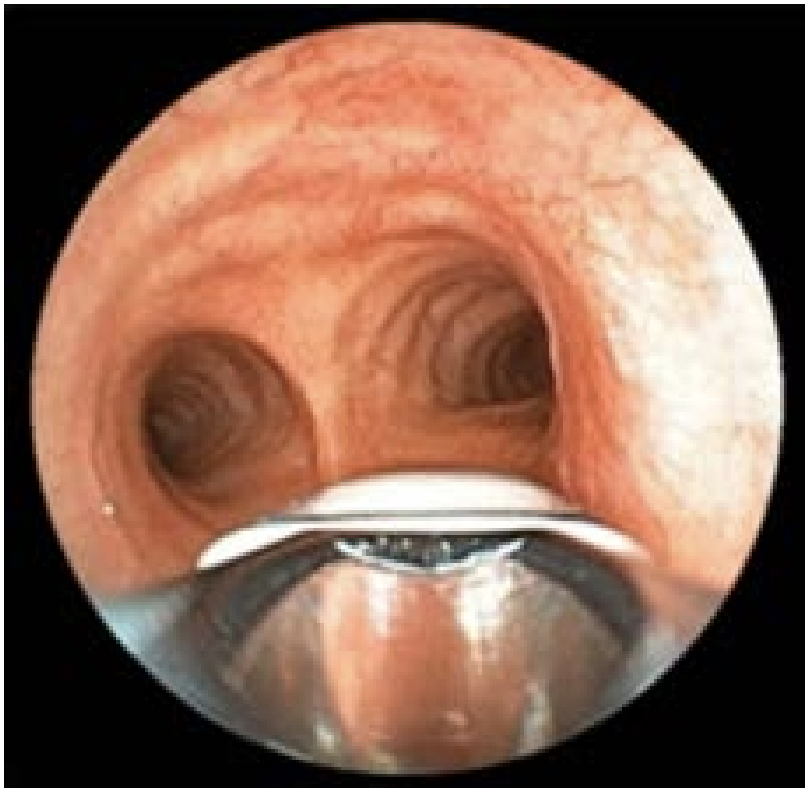

Linear/Convex Probe EBUS

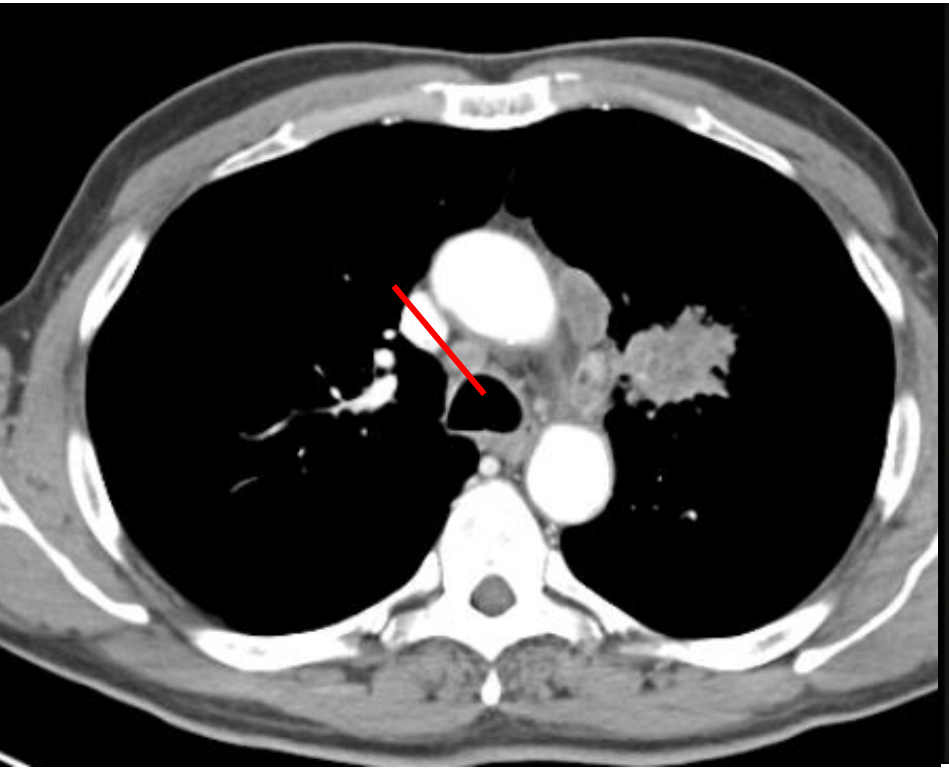

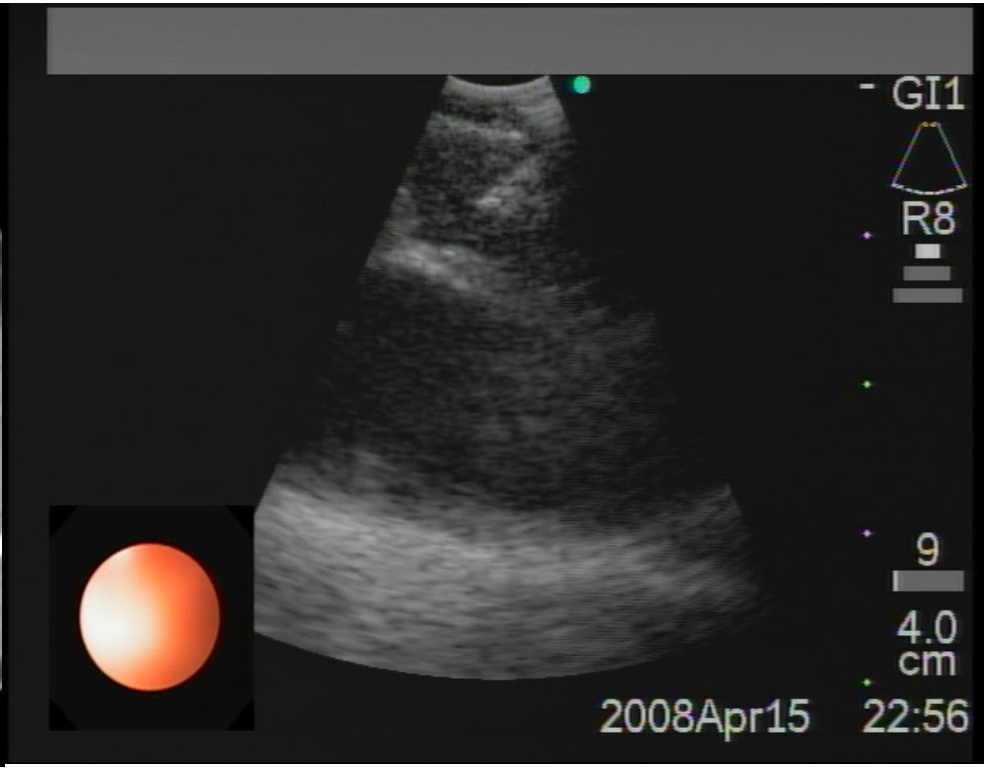

Mediastinal Lymph Node Map

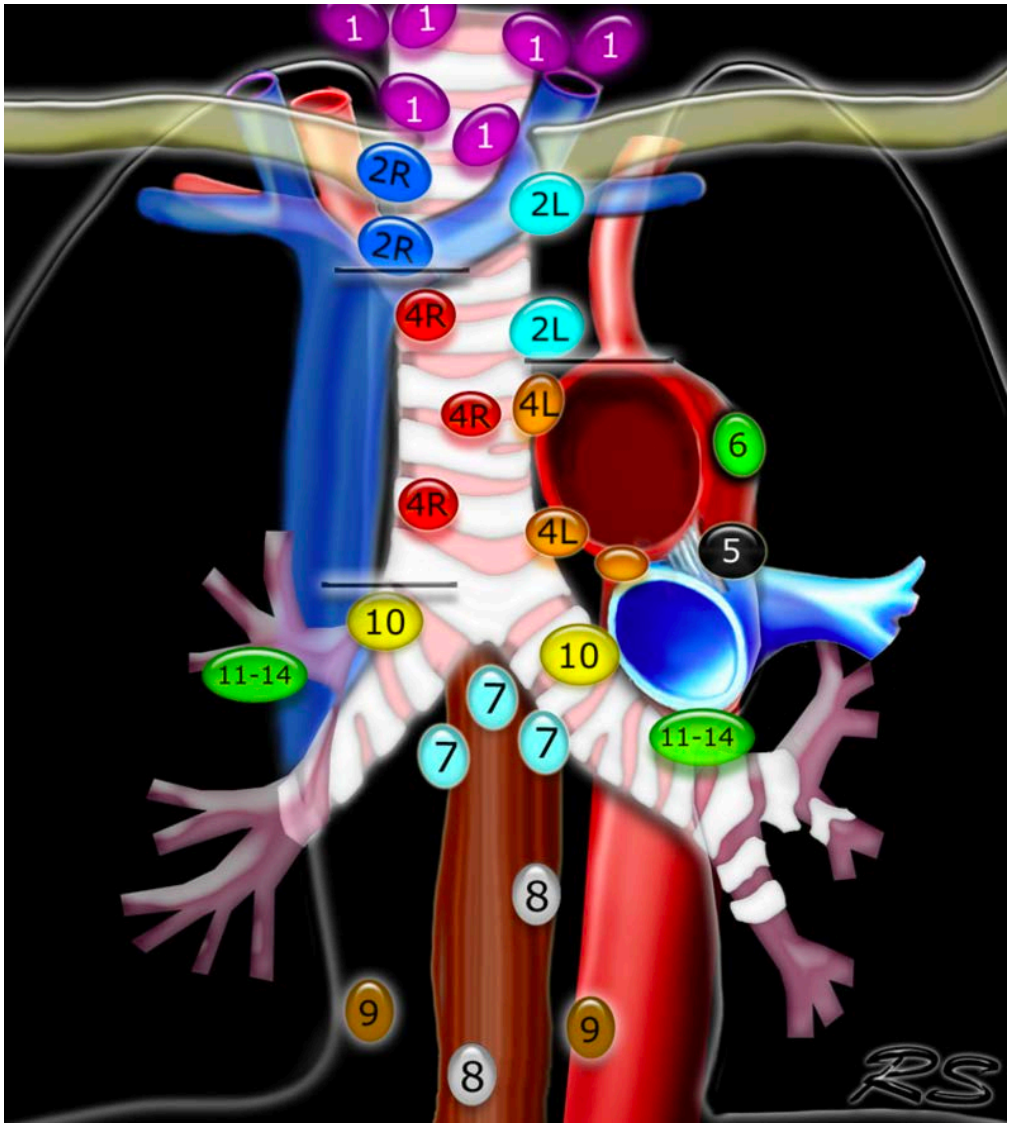

University of Pittsburgh

EBUS Indications

- Mediastinal Lymph Node Biopsy:
  - Lung cancer staging, diagnosis, molecular marker collection
  - Thoracic lymph node metastasis
  - Lymphoma
  - Lymph node cultures
  - Sarcoidosis
- Central lung mass

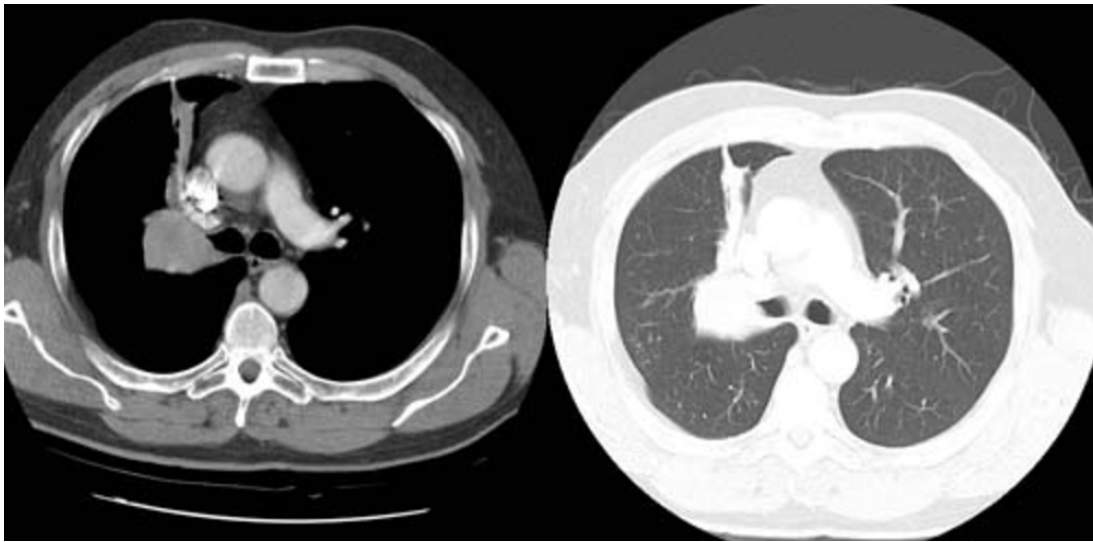

EBUS Contraindications

- Absolute:
  - Difficult/Complex/Unstable Airway
  - Active mediastinitis

- Relative
  - Hypoxia (> 6 LNC)
  - Coagulopathy: Plts < 50, INR > 1.7
  - Full dose anticoagulation
  - Clopidogrel/prasugrel

EBUS Complications

- Bleeding
  - Airway
  - Mediastinal hematoma
- Pneumothorax
- Pneumomediastinum
- Vocal Cord Injury
- Infection:
  - PNA/Mediastinitis
- Foreign Body

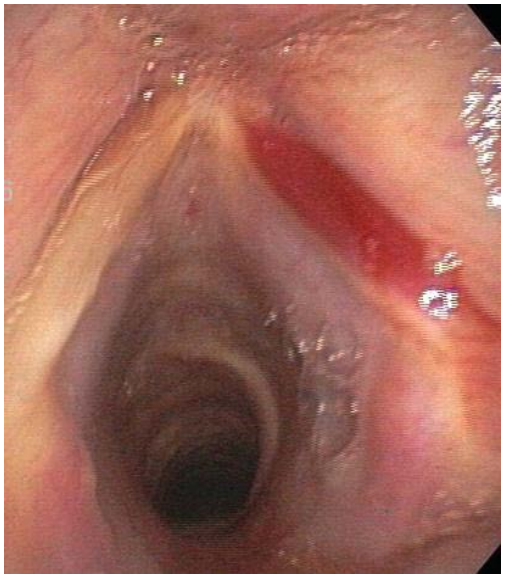

Radial Probe EBUS

- Small (< 2mm) probe with a rotating ultrasound at the tip that provides a 360 degree view outside of a peripheral airway.
  - Used to localize peripheral lung nodules/lesions

Radial Probe EBUS

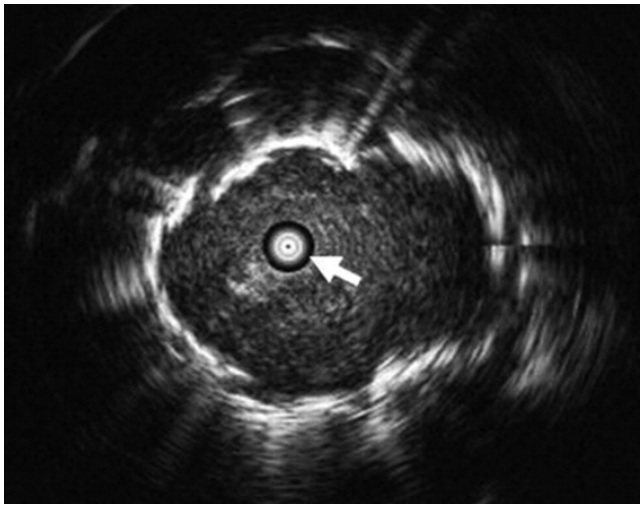

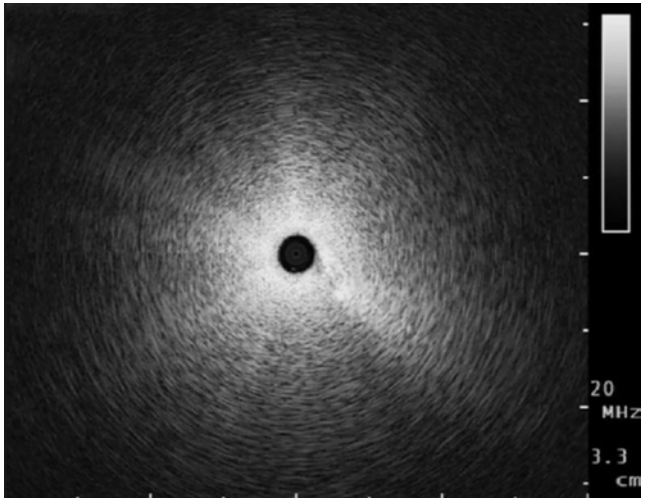

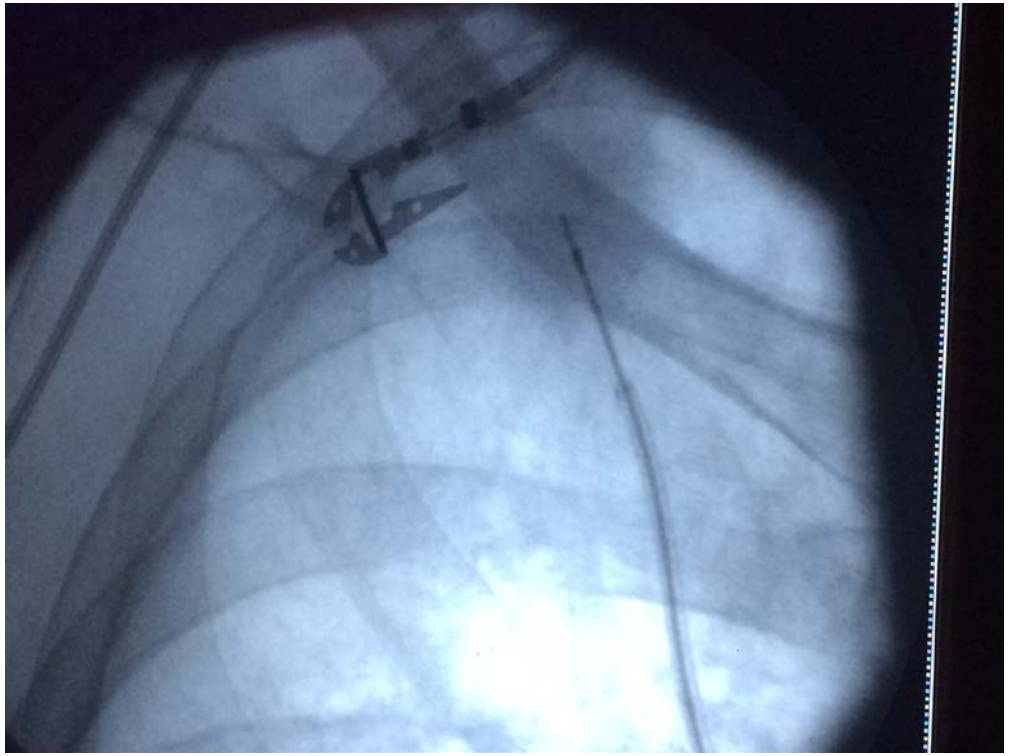

Advanced Diagnostic Bronchoscopy

- Endobronchial ultrasound (EBUS):
- Electromagnetic navigational bronchoscopy
- Electromagnetic virtual CT TTNA

Electromagnetic Navigational Bronchoscopy

- The use of a virtual bronchoscopic tree reconstructed from a CT of the Chest paired to a patients' anatomic bronchial tree to guide biopsy of a peripheral lesion/nodule.

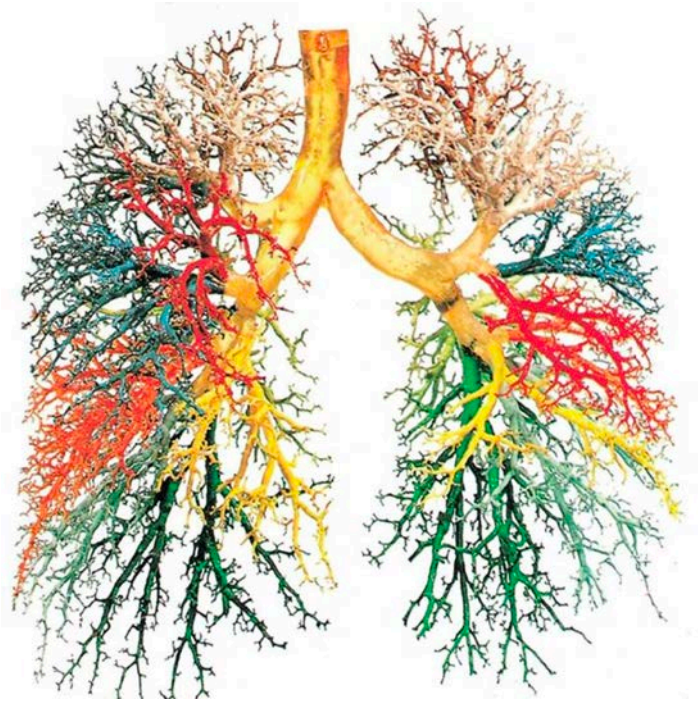

University of Pittsburgh

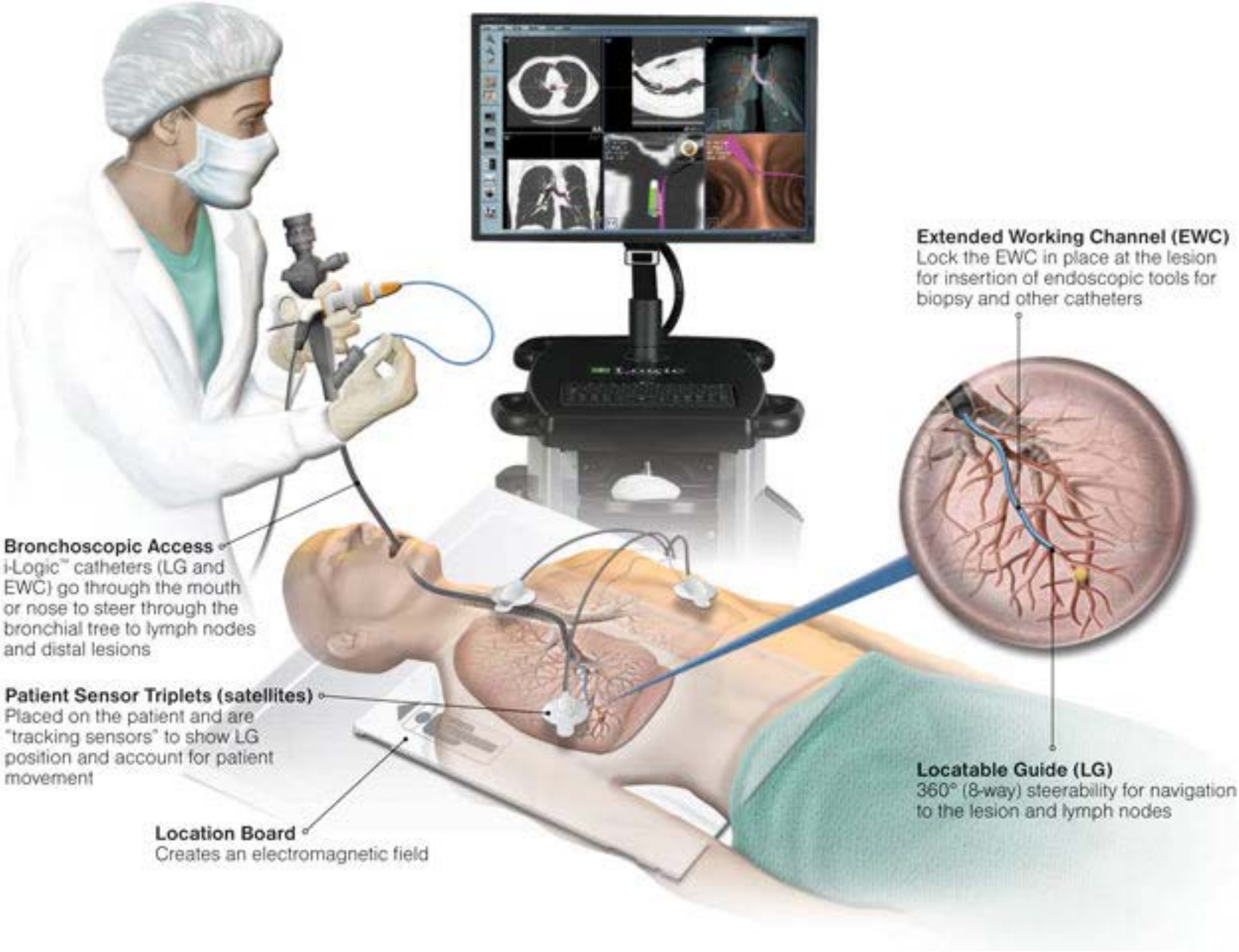

University of Pittsburgh

Electromagnetic Navigational Bronchoscopy

- Allows increased accuracy for smaller peripheral lesions.
- Used in conjunction with radial EBUS and Fluoro
- Generally done under general anesthesia
- Guides peripheral biopsy for path/cyto/micro using:
  - Cyto/Micro Brushing and Washing
  - FNA
  - Forceps
  - Shaving tool

Electromagnetic Navigational Bronchoscopy

- Contraindications:
  - Same as standard bronchoscopy:
    - Hypoxia
    - Coagulopathy
    - Hemodynamic instability
    - Airway compromise
  - Initially presence of a pacemaker/AICD considered an relative contraindication.

Electromagnetic Virtual CT TTNA

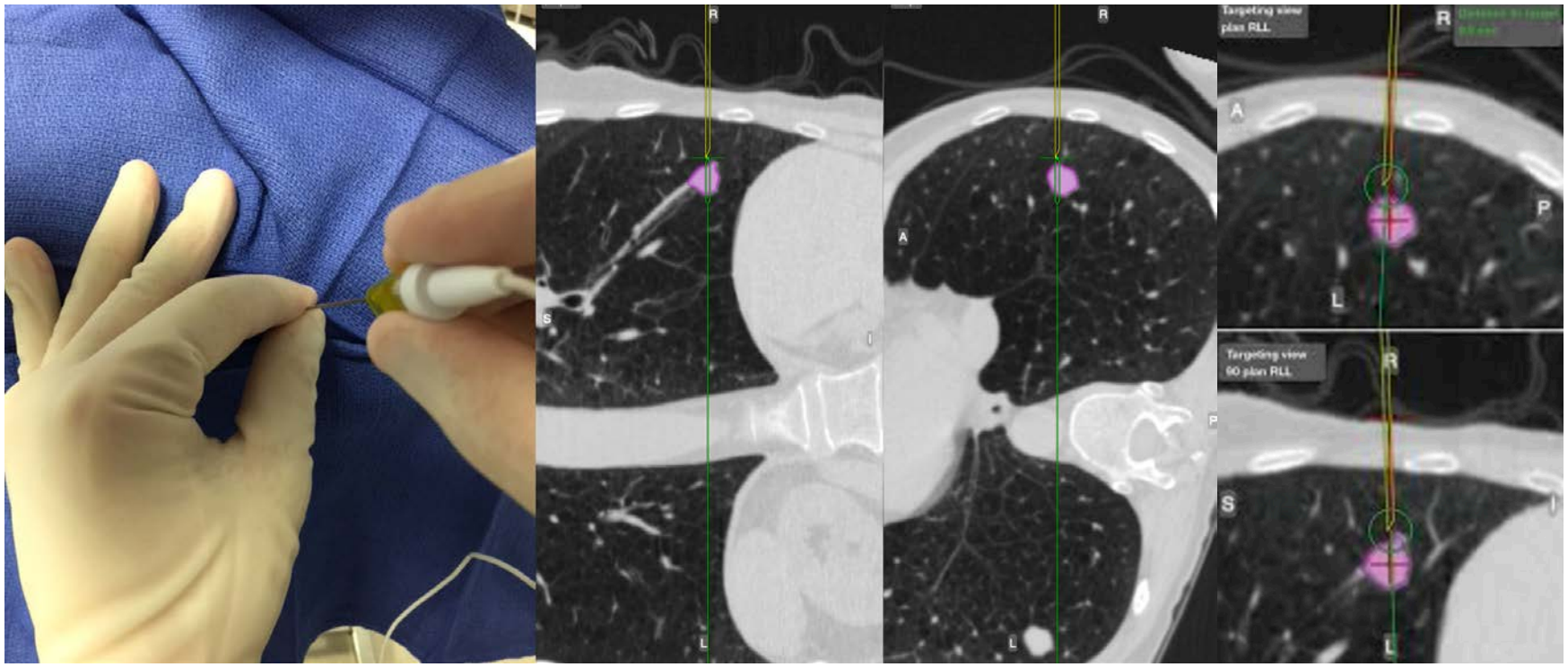

University of Pittsburgh

Lung Nodule Workflow

Begin with EBUS guided TBNA of any Enlarged Mediastinal Lymph Nodes

Proceed to EMN Guided Bronchoscopic Biopsy

Proceed to EMN guided TTNA

If positive on ROSE procedure is complete

Therapeutic Bronchoscopy

- Can be performed with flexible or rigid bronchoscopy

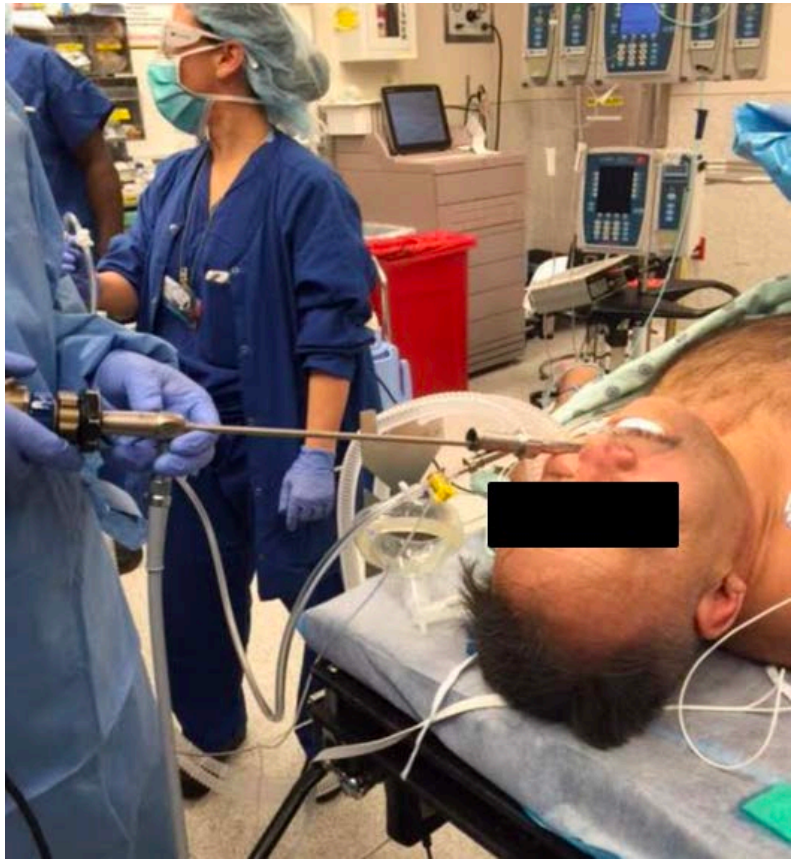

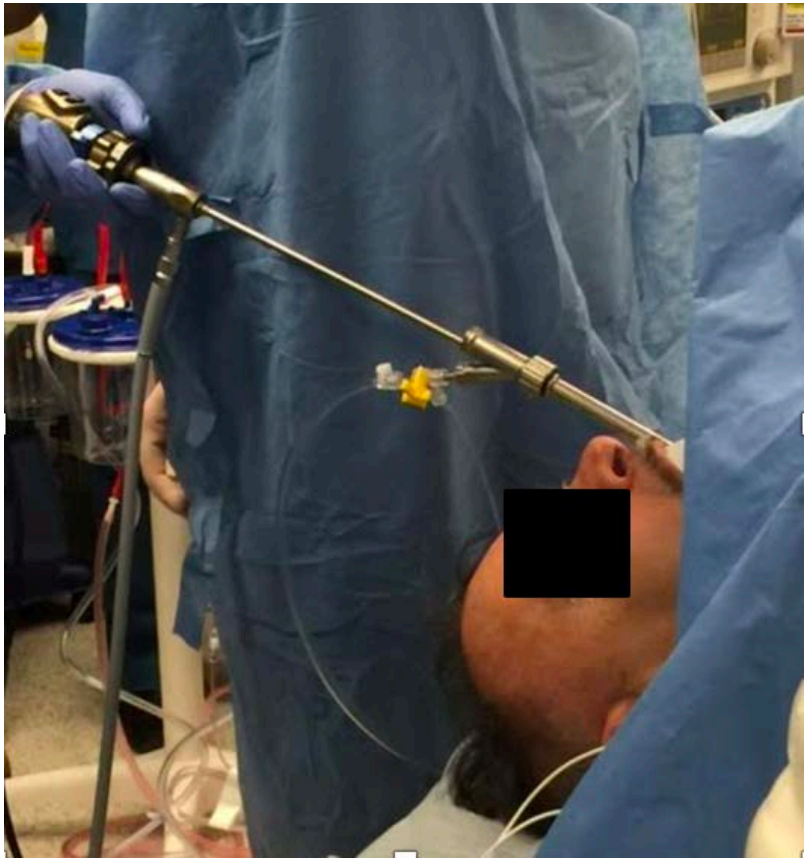

Central Airway Obstruction

- Definition: Narrowing of the lumen of the trachea, or mainstem bronchi causing air flow limitation

- Etiologies:
  - Malignant
  - Idiopathic
  - Lymphadenopathy
  - Infection
  - Vascular compression
  - Post transplant
  - Amyloid
  - GPA
  - Mucus plug
  - Sarcoidosis
  - Relapsing polychondritis
  - Iatrogenic
    - stents
    - stenosis post-intubation or tracheostomy

Symptoms/Diagnosis

- Symptoms:
  - Chronic, sub-acute or acute
  - Wheezing: Potential for misdiagnosis
    - Refractory to bronchodilators
  - Dyspnea:
    - Exertion: airway < 8 mm
    - Rest/stridor: airway < 5 mm
- Diagnosis:
  - Exam, PFT's, CT, bronchoscopy

Hollingsworth, Clin Chest Med 1987; 8: 231

Central Airway Obstruction

- Definition: Narrowing of the lumen of the trachea, or mainstem bronchi causing air flow limitation

- Etiologies:
  - Malignant
  - Idiopathic
  - Lymphadenopathy
  - Infection
  - Vascular compression
  - Post transplant
  - Amyloid
  - GPA
  - Mucus plug
  - Sarcoidosis
  - Relapsing polychondritis
  - Iatrogenic
    - stents
    - stenosis post-intubation or tracheostomy

Central Airway Obstruction

- Definition: Narrowing of the lumen of the trachea, or mainstem bronchi causing air flow limitation

- Etiologies:

  - Malignant

Central Airway Obstruction

- Definition: Narrowing of the lumen of the trachea, or mainstem bronchi causing air flow limitation

- Etiologies:
  - Malignant
  - Idiopathic
  - Lymphadenopathy
  - Infection
  - Vascular compression
  - Post transplant
  - Amyloid
  - GPA

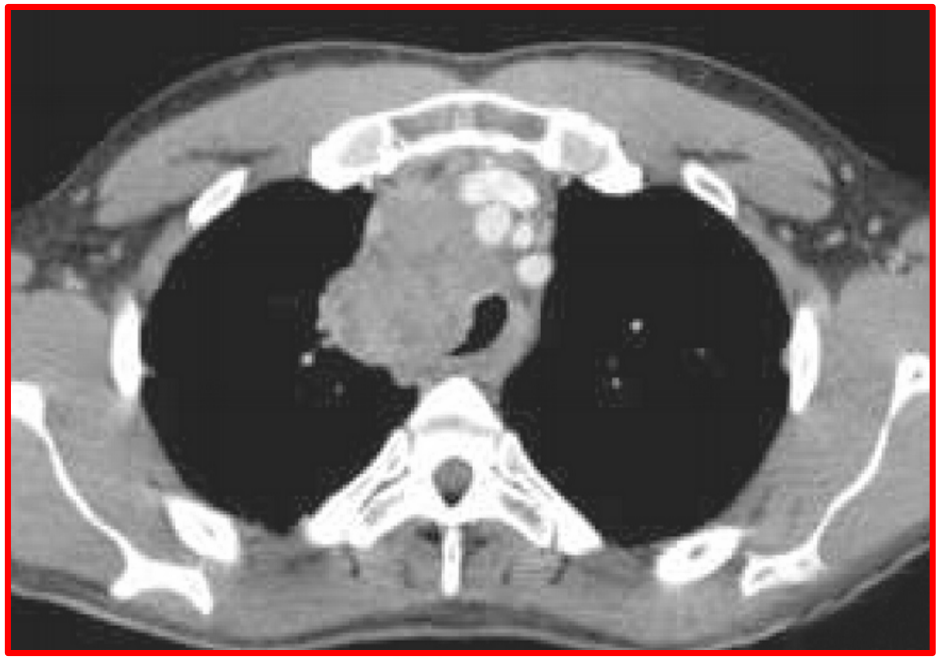

Bloch et al. Eur Resp Rev. 2009

Central Airway Obstruction

- Definition: Narrowing of the lumen of the trachea, or mainstem bronchi causing air flow limitation

- Etiologies:
  - Malignant
  - Idiopathic
  - Lymphadenopathy
  - Infection
  - Vascular compression
  - Post transplant
  - Amyloid
  - GPA

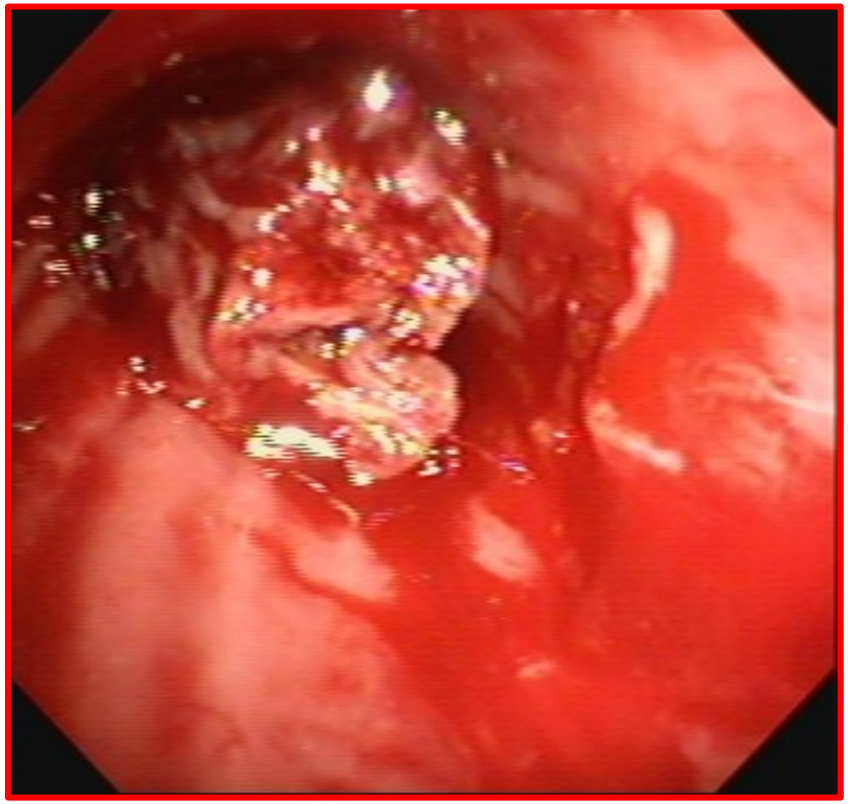

Central Airway Obstruction

- Definition: Narrowing of the lumen of the trachea, or mainstem bronchi causing air flow limitation

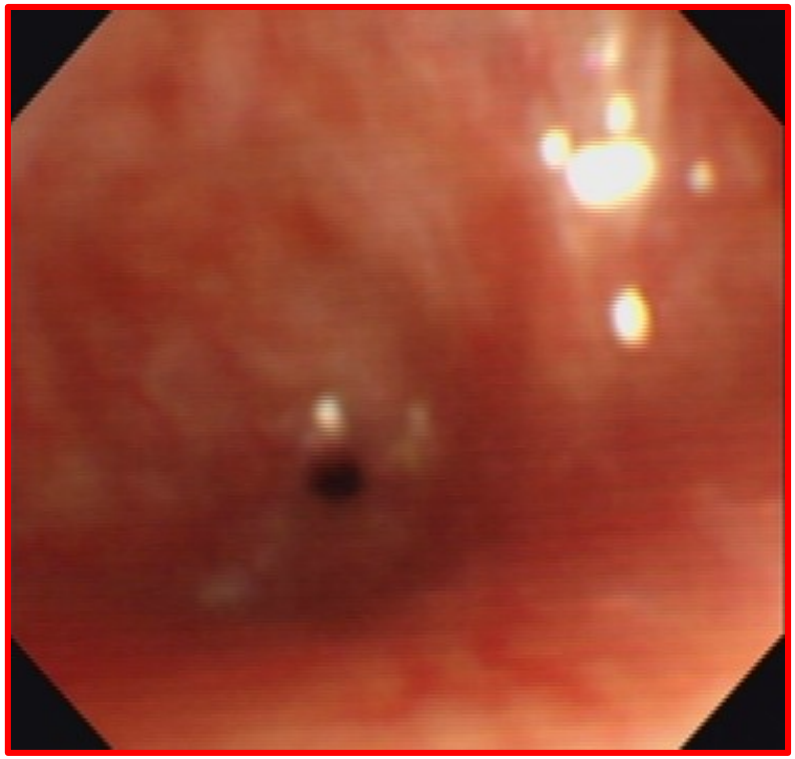

- Mucus plug
- Sarcoidosis
- Relapsing polychondritis
- Iatrogenic
  - stents
  - stenosis post-intubation or tracheostomy

University of Pittsburgh

Central Airway Obstruction

- Definition: Narrowing of the lumen of the trachea, or mainstem bronchi causing air flow limitation

- Mucus plug
- Sarcoidosis
- Relapsing polychondritis
- Iatrogenic
  - stents
  - stenosis post-intubation or tracheostomy

University of Pittsburgh

Central Airway Obstruction

- Definition: Narrowing of the lumen of the trachea, or mainstem bronchi causing air flow limitation

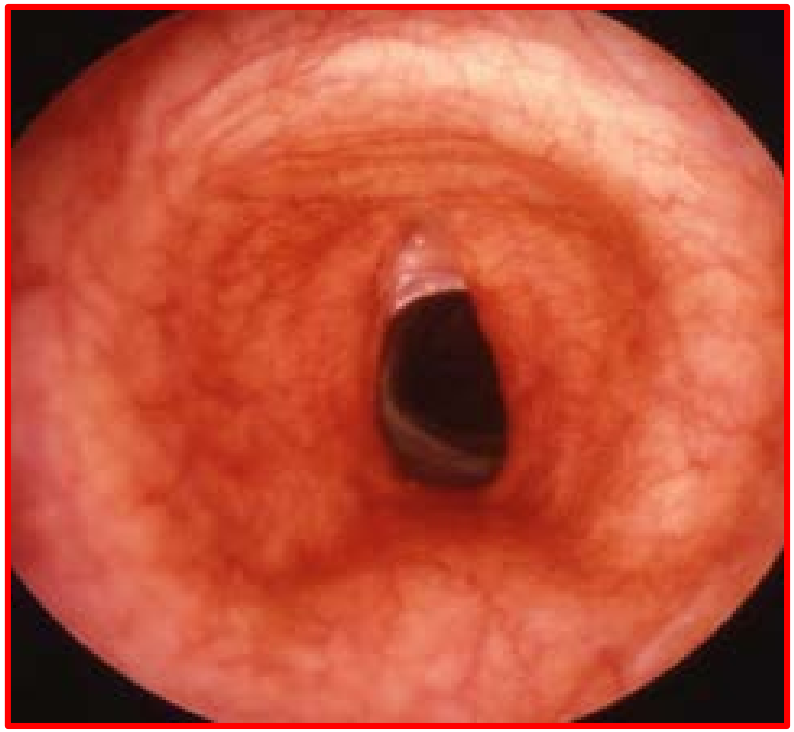

- Mucus plug
- Sarcoidosis
- Relapsing polychondritis
- Iatrogenic
  - stents
  - stenosis post-intubation or tracheostomy

University of Pittsburgh

Management of Non-Malignant CAO

- The only definitive management is tracheal resection

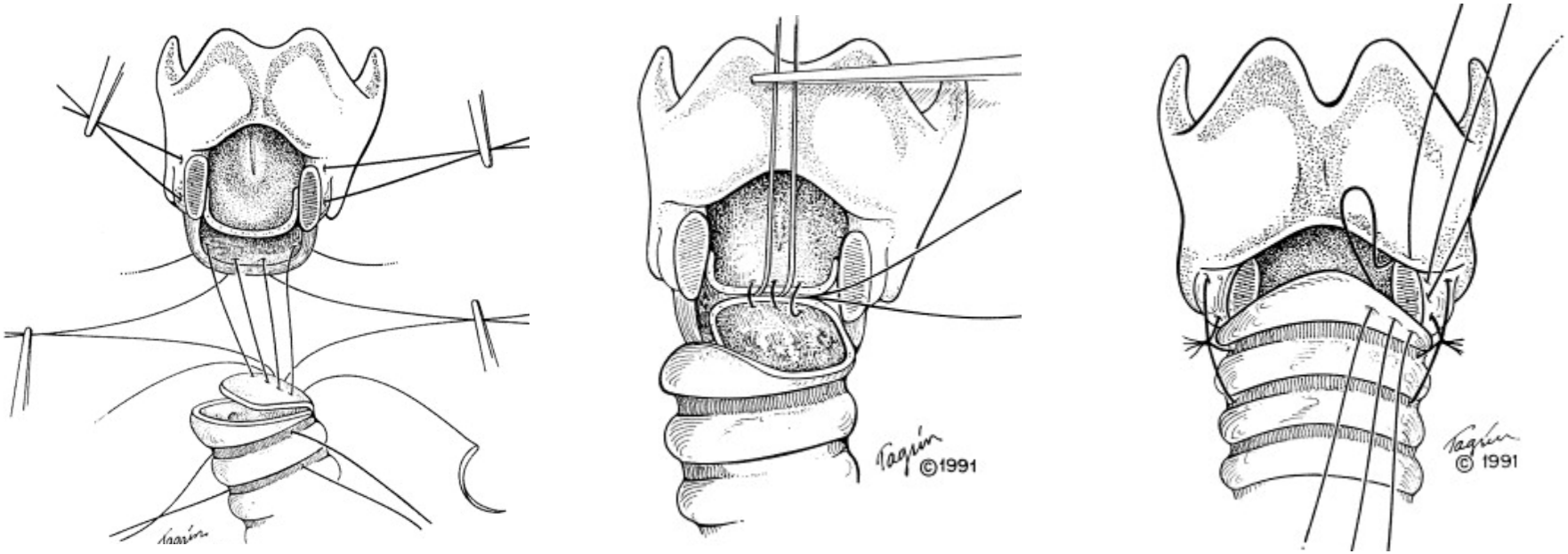

Ashiku et al. J Thorac Cardiovasc Surg. 2004;127

University of Pittsburgh

Tracheal Resection

- Review of 901 patients over 28 years at MGH
  - Death: 11 patients (1%)
  - Re-stenosis: 37 patients (4%)
    - Dilation: 2
    - Tracheostomy: 7
    - T- tube: 20
    - Re-operation: 16

Wright et al. J Thorac Cardiovasc Surg. 2004 Nov;128(5):731-9

Non-Surgical Management of CAO

- Rigid and Flexible Bronchoscopy with:
  - Balloon dilation
  - Laser resection
  - Argon plasma Coagulation
  - Electrocautery
  - Cryoprobe therapy
  - Covered Metal Stenting
  - Topical or injectable anti-proliferative/fibrotic agents

- Rigid Only:
  - Micro-debrider
  - Rigid dilation and tumor coring
  - Silicone Stenting

Therapeutic Bronchoscopy

- Rigid bronchoscopy
  - Central airway obstruction (CAO)
    - Dilation
    - Tumor excision, destruction
    - Airway stenting
  - Foreign body removal

- Non Surgical Modalities for endoscopic treatment of CAO
  - Majority can be done with flexible or rigid bronchoscopy

Metallic Airway Stenting

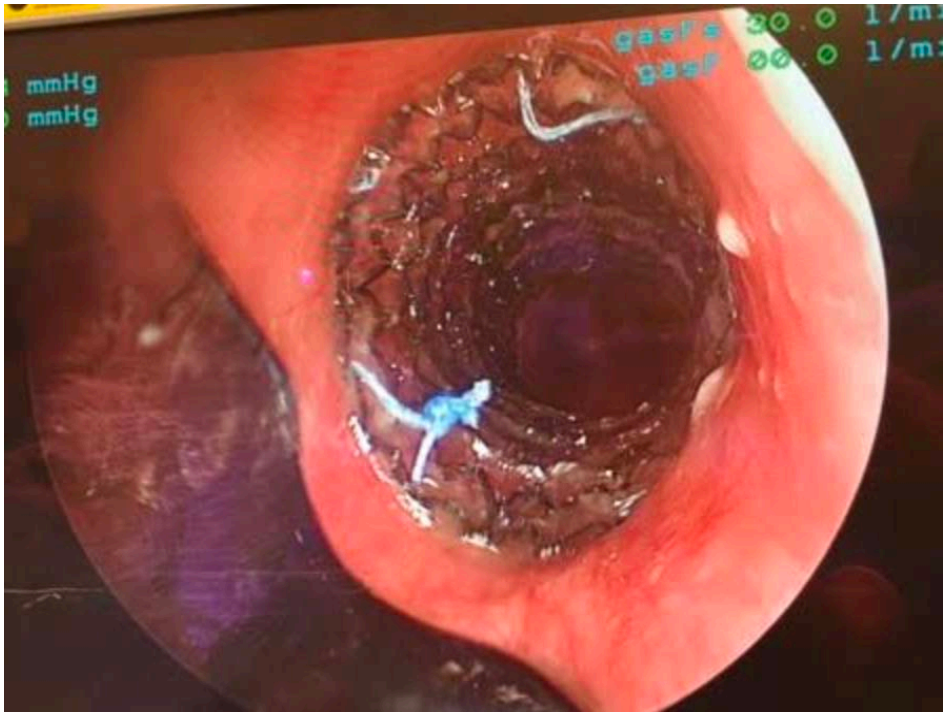

Advanced Airway Management with Silicone Stenting



University of Pittsburgh

Silicone Stenting

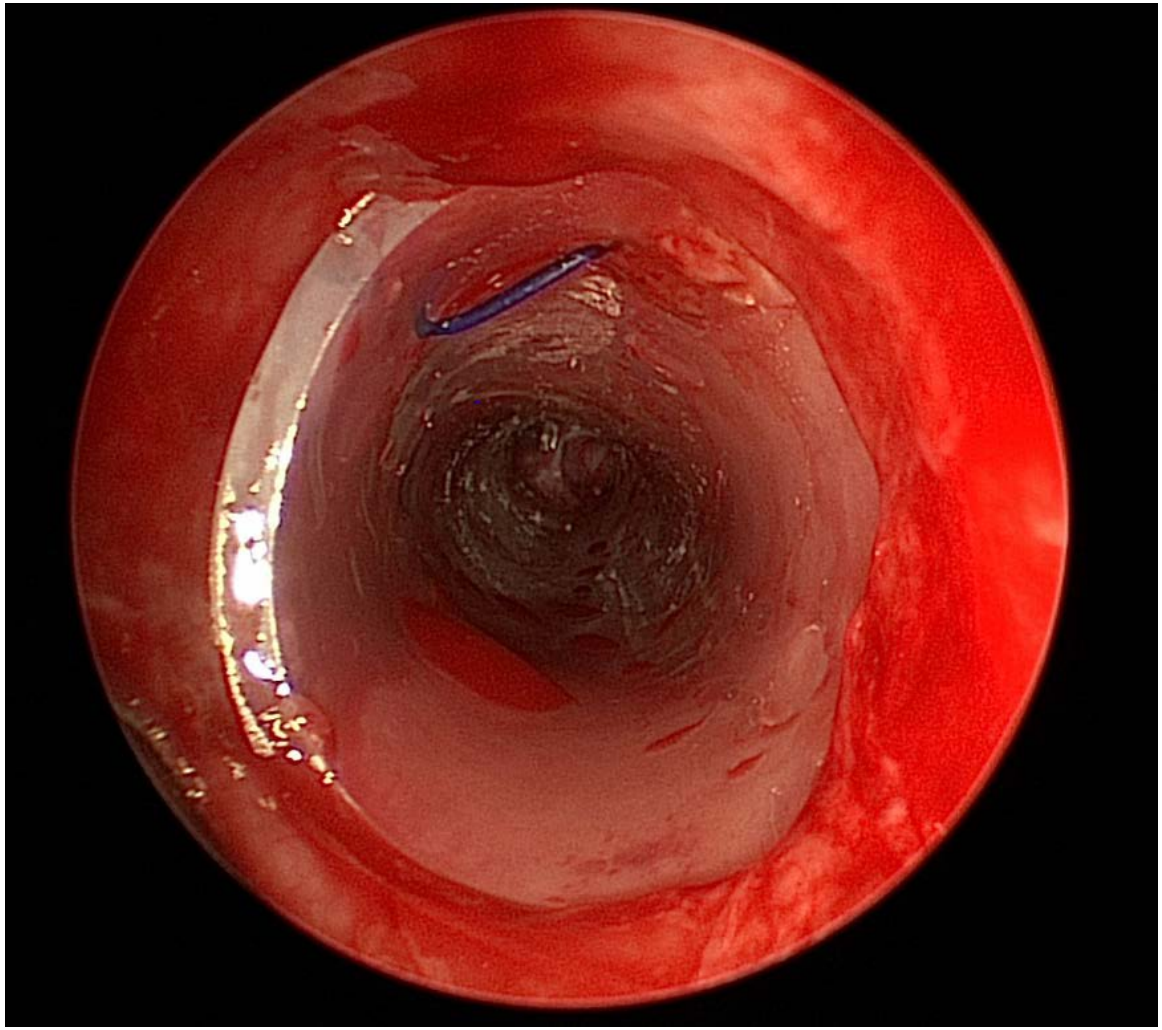

Advanced Airway Management Case

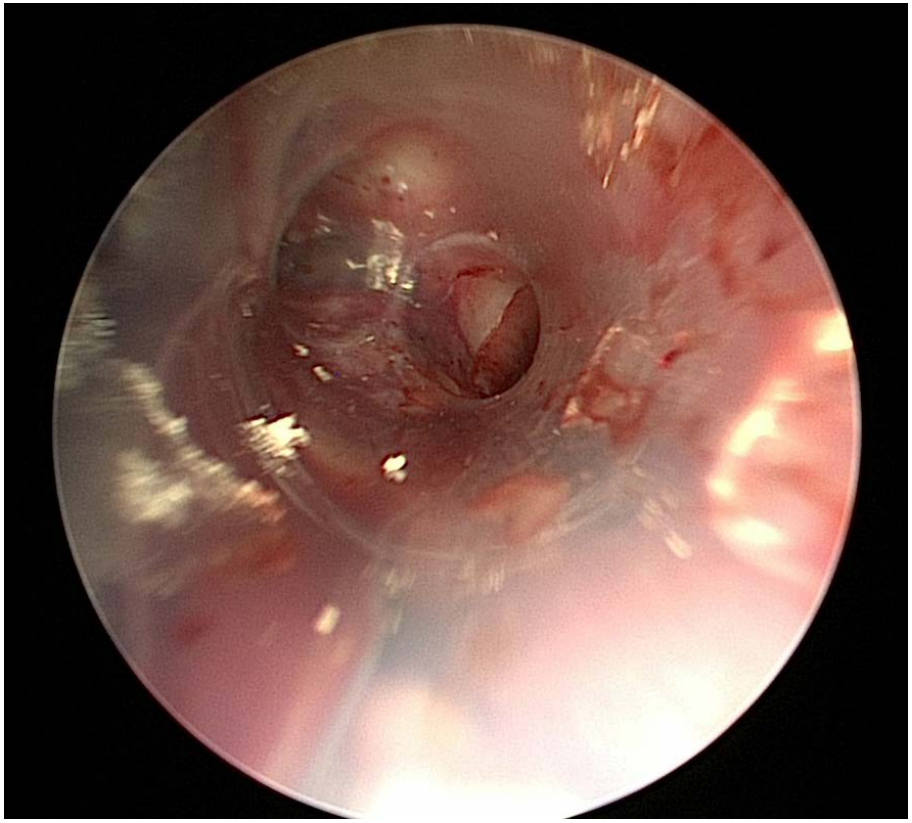

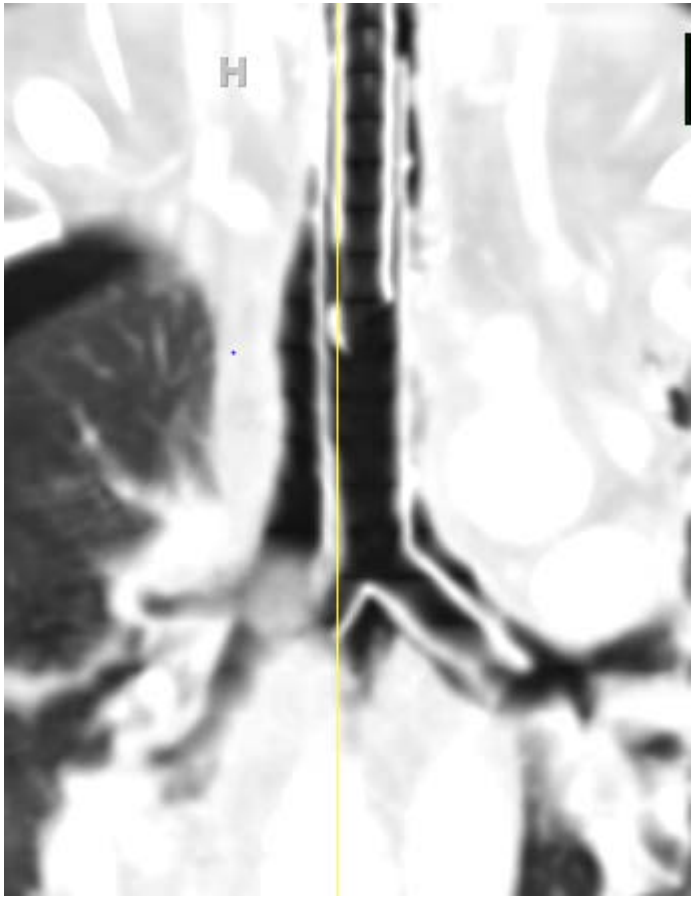

Non-Surgical Management of CAO

- Rigid and Flexible Bronchoscopy with:
  - Balloon dilation
  - Laser resection
  - Argon plasma Coagulation
  - Electrocautery
  - Cryoprobe therapy
  - Covered Metal Stenting
  - Topical or injectable anti-proliferative/fibrotic agents

- Rigid Only:
  - Micro-debrider
  - Rigid dilation and tumor coring
  - Silicone Stenting

Non-Surgical Management of CAO

- Rigid and Flexible Bronchoscopy with:
  - Balloon dilation
  - Laser resection
  - Argon plasma Coagulation
  - Electrocautery
  - Cryoprobe therapy
  - Covered Metal Stenting
  - Topical or injectable anti-proliferative/fibrotic agents

- Rigid Only:
  - Micro-debrider
  - Rigid dilation and tumor coring
  - Silicone Stenting

Blowfish Transbronchial Micro-Infusion Catheter

- Sterile, single use catheter
- Advanced down flexible bronchoscope
- Uninflated: micro-infusion needle is sheathed by balloon
- Inflation: causes needle to project perpendicular to plane of catheter
- Originally developed for endovascular injection

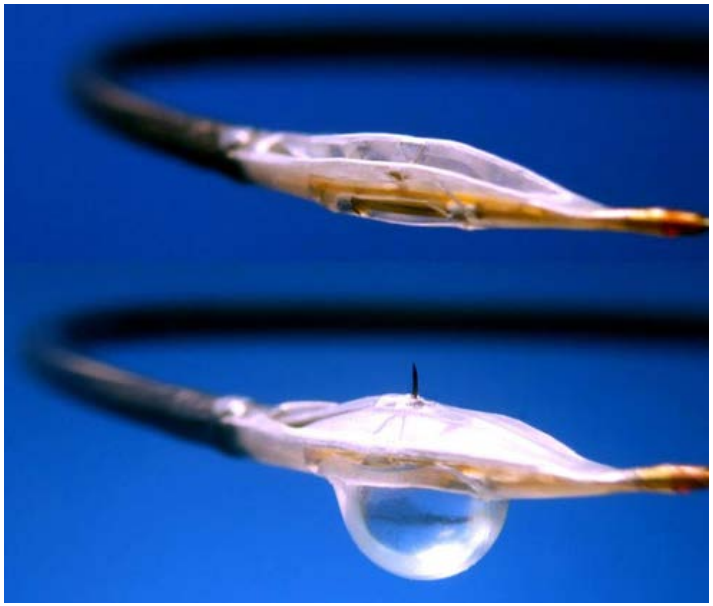



University of Pittsburgh

Blowfish Transbronchial Micro-Infusion Catheter

- Animal pilot study
- Injection of methylene blue
- 60% circumferential spread of agent through tracheal wall
- No peri-operative morbidity

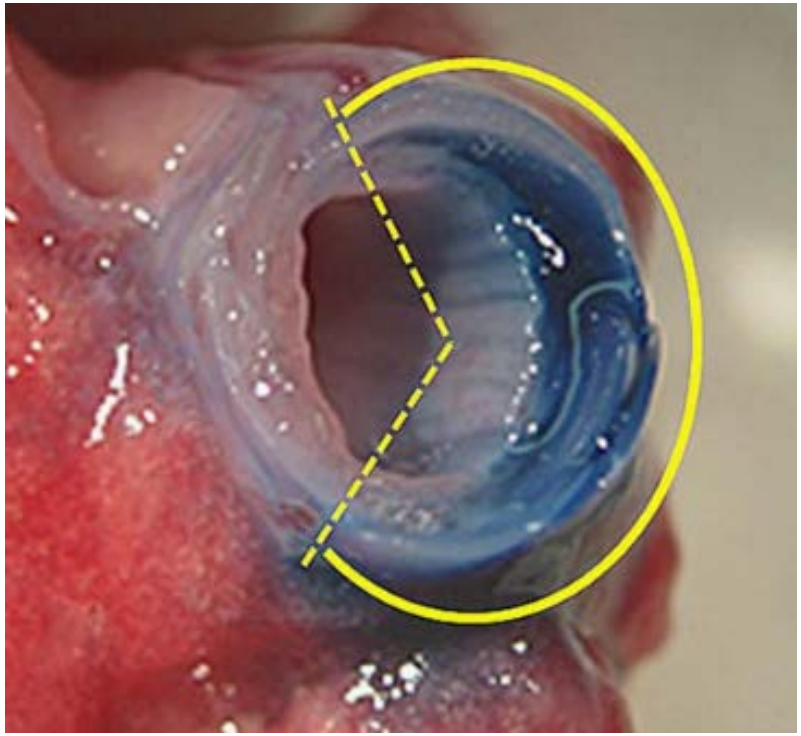

University of Pittsburgh

Tsukada et al. J Bronchology Interv Pulmonol. 2015 Oct;22(4):312-8

BROADWAY Trial:

- Promising Preliminary Results:
  - 49 yo w/ stage IV NSCLC at diagnosis
  - 3rd Patient Enrolled
  - Right hilar mass: 95% RMSB obstruction
  - 6/2014: Diagnosed
  - 8/2014: BROADWAY
  - Today: Still alive, doing well!

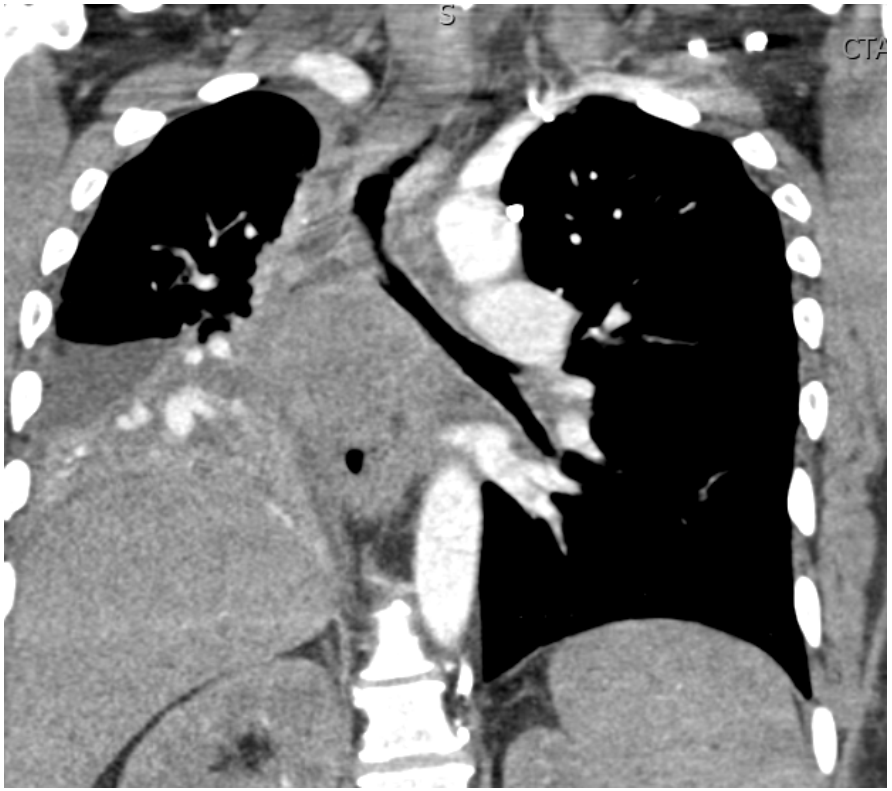

BROADWAY Trial:

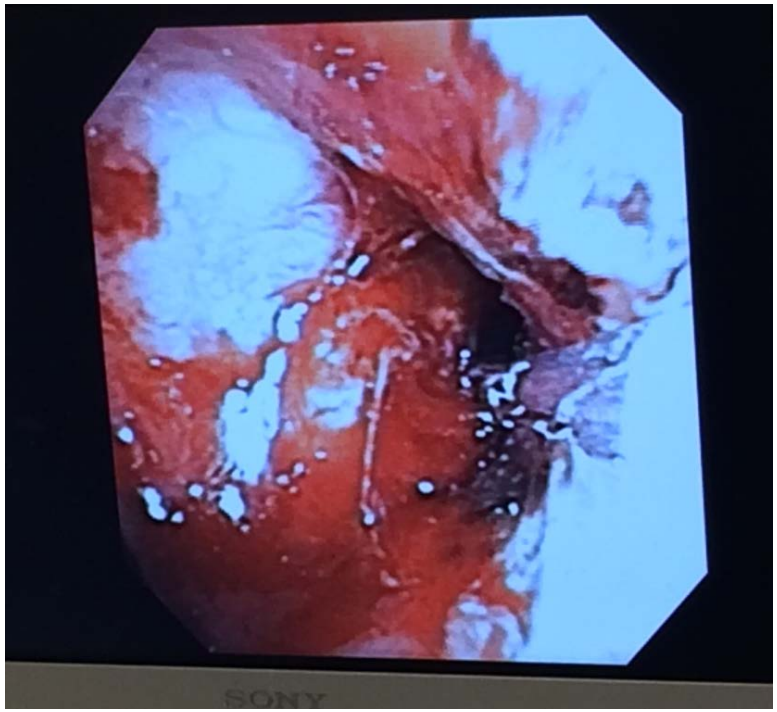

Day of Injection

6 Months Post

University of Pittsburgh

Minimally Invasive Pleural Procedures

- Medical thoracoscopy
  - Pleural biopsy
  - Pleurodesis
- Closed pleural biopsy
- Tunneled pleural catheters
- Pigtail and surgical chest tube insertion
- Thoracentesis
- Intrapleural thrombolytics for complex pleural infection

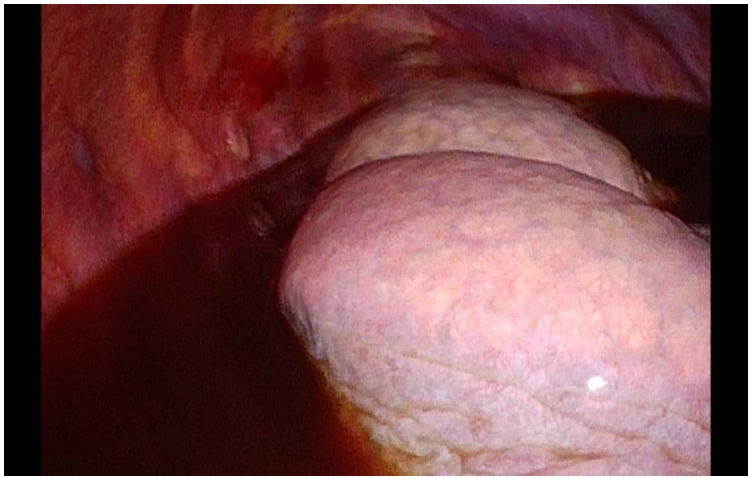

Roy W. Semaan, M.D.
Director, Interventional Pulmonology
Assistant Professor of Medicine
Division of Pulmonary Allergy & Critical Care Medicine
University of Pittsburgh Medical Center

Pager: 412-958-7477
Cell: 571-334-6915

University of Pittsburgh